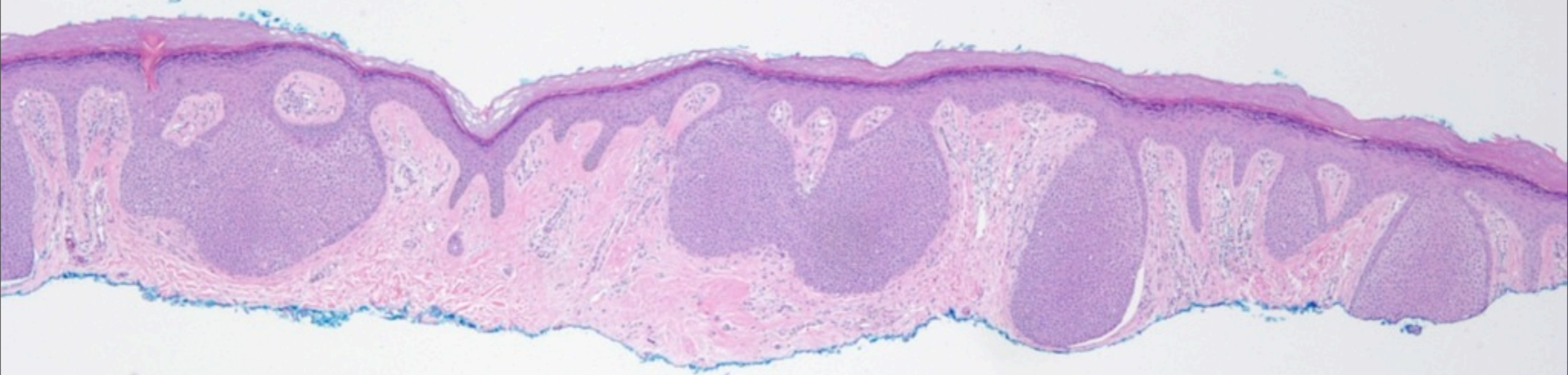
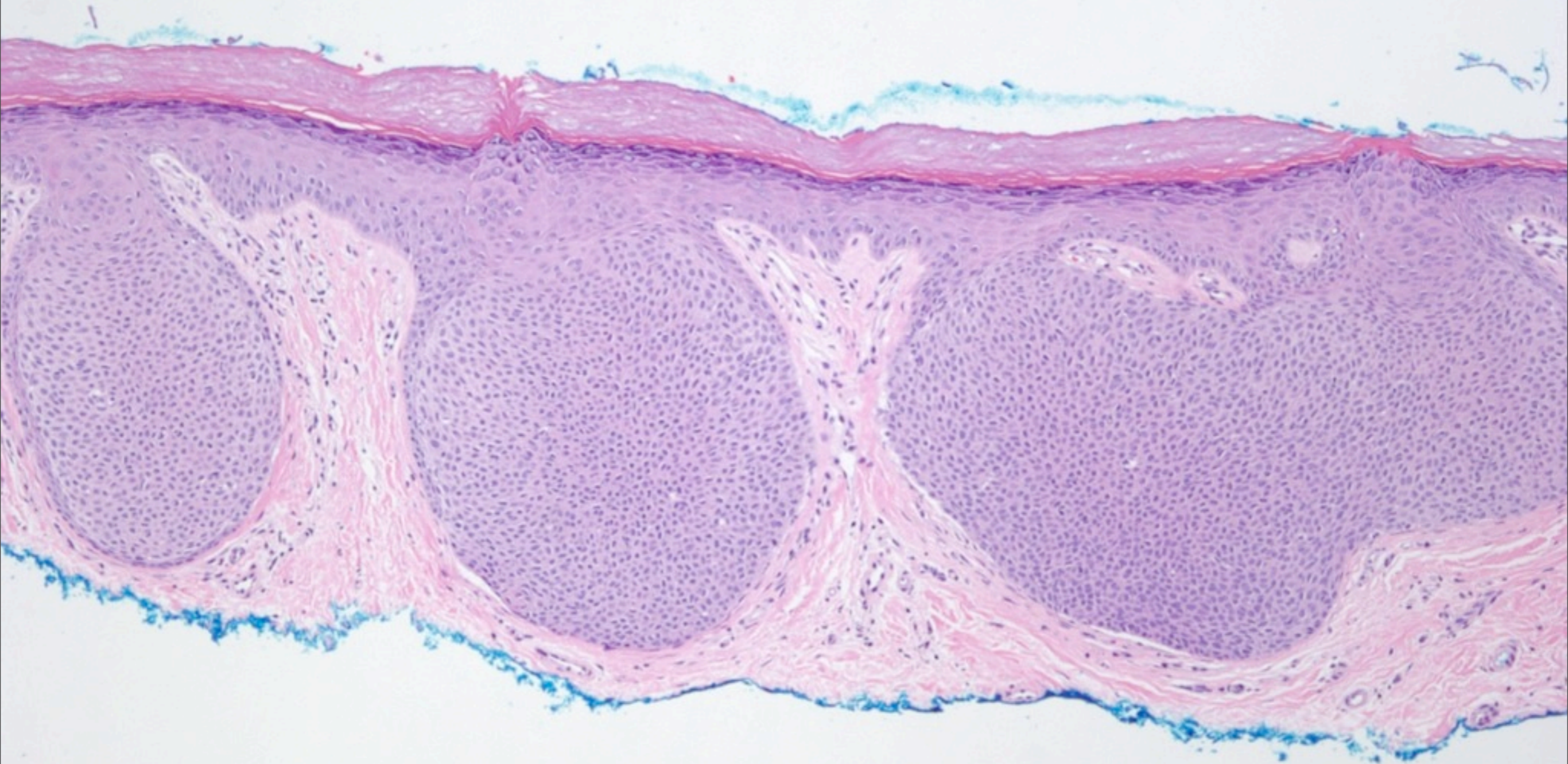
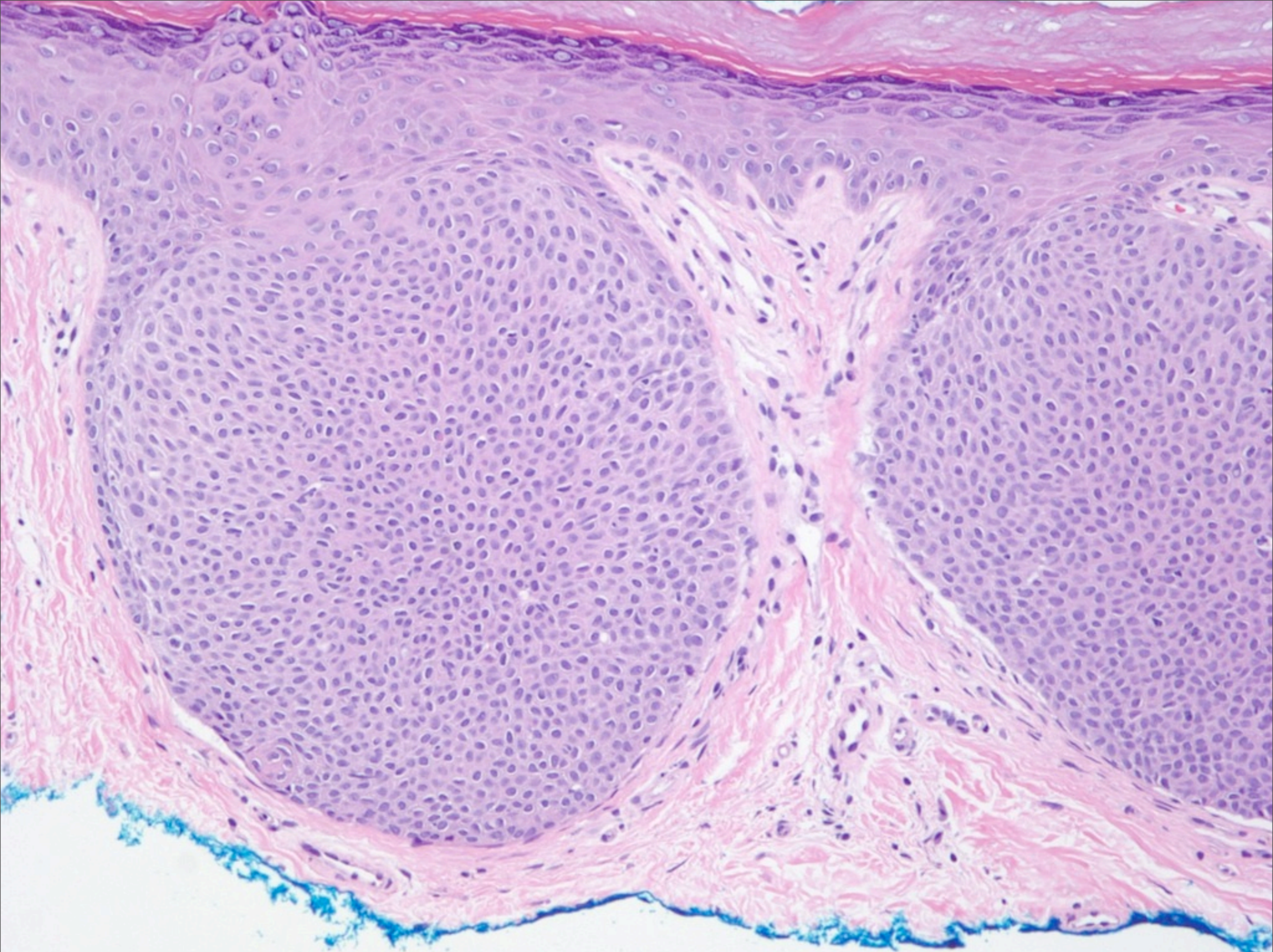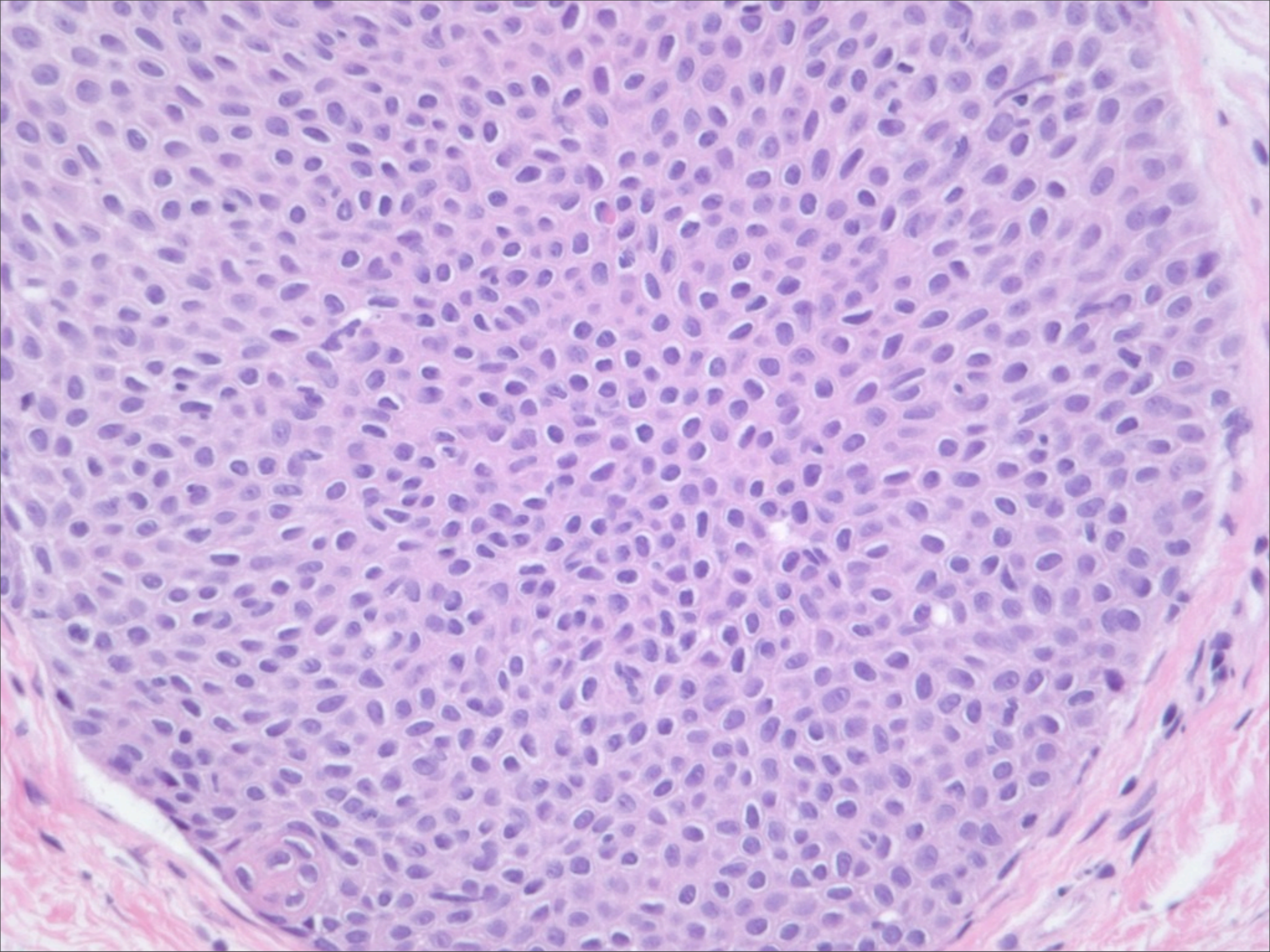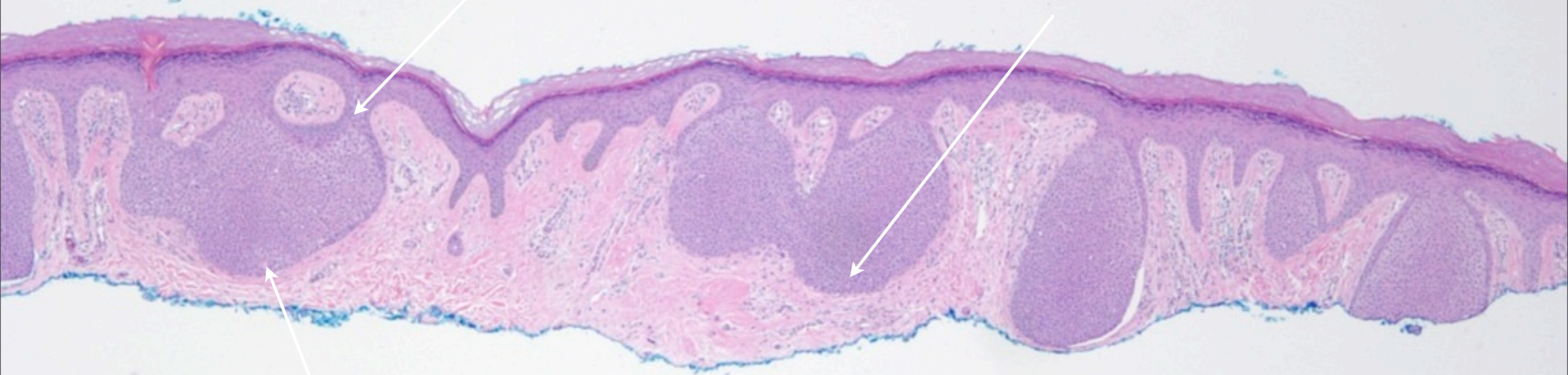
What is the best diagnosis?

- Hidroacanthoma simplex
- Seborrheic keratosis
- Condyloma
- Bowen's disease
- Basal cell carcinoma

Hidroacanthoma Simplex

“Clonal” proliferation of keratinocytes

Lacks flattened silhouette of SK



Focal Ductal Differentiation